# Fibroblast Foci Are Not Discrete Sites of Lung Injury or Repair

## The Fibroblast Reticulum

**Carlyne D. Cool, Steve D. Groshong*, Pradeep R. Rai*, Peter M. Henson, J. Scott Stewart, and Kevin K. Brown**

Departments of Medicine and Pathology, University of Colorado Health Sciences Center; and Interstitial Lung Disease Program, National Jewish Medical and Research Center, Denver, Colorado

*Background:* **Usual interstitial pneumonia (UIP), the pathologic correlate of idiopathic pulmonary fibrosis, contains characteristic discrete areas of fibroblasts, myofibroblasts, and newly formed collagen, termed "fibroblast foci." These lesions are argued to represent isolated sites of recurrent acute lung injury and suggested to be the mechanism of disease progression. We hypothesized that, rather than isolated, these lesions are part of an organized neoplasm.**

*Methods:* **Morphometric analysis of pentachrome-stained histologic sections of UIP was performed. Using point-counting technique on serial sections, fibroblast foci, arteries, and macrophage clusters were identified and we determined their individual "connectiveness" by estimating the Euler number. Two-dimensional micrographs were collated into a three-dimensional array from which a visual three-dimensional reconstruction could be constructed. Clonality analysis was performed using human androgen receptor gene methylation assay.**

*Results:* **Blood vessels show significant connectivity with a Euler number of 2, whereas macrophage clusters exhibited no connectivity. The fibroblast foci showed a high level of interconnection with Euler numbers ranging from 19 to 39. The computer generated three-dimensional models provide a visual confirmation of this connectiveness. Human androgen receptor gene methylation assay analysis of the foci showed balanced methylation consistent with polyclonality.**

*Conclusions:* **The fibroblast foci of UIP are the leading edge of a complex reticulum that is highly interconnected and extends from the pleura into the underlying parenchyma. It is a reactive, rather than a malignant, process.**

**Keywords:** fibroblast foci; fibroblast reticulum; idiopathic pulmonary fibrosis; usual interstitial pneumonia

Idiopathic pulmonary fibrosis (IPF) is a progressive fibrosing interstitial pneumonia of unknown etiology with a median survival of 3 yr (1). Histopathologically, it is defined by a specific pattern on surgical lung biopsy, usual interstitial pneumonia (UIP). Although IPF is a disease of unknown etiology, the current hypothesis regarding its development conceptualizes ongoing multiple, small, focal, and isolated episodes of epithelial injury followed by a pathologic fibrotic repair mechanism (2).

The clinical features of IPF—insidious onset, progression over years, infrequent but abrupt episodes of deterioration (3), and failure to respond to immunosuppressive therapy—have offered indirect evidence in support of this hypothesis. More substantial support comes from the histopathologic features of the disease. UIP is characterized by a temporally heterogeneous appearance with areas of normal appearing lung intermixed with older collagenized fibrosis, microscopic honeycombing, and small focal areas of younger, myxoid-appearing matrix with aggregates of actively proliferating and collagen-producing myofibroblasts termed "fibroblast foci" (4–6). These foci are often identified in a transition zone between the more normal uninvolved lung and the abnormal fibrotic lung. They have been interpreted to represent an organizing phase of focal acute lung injury (5, 7, 8) and believed to recapitulate the events that typify the healing skin wound (9). These foci are clinically and biologically important in the progression of disease; their numbers on surgical lung biopsy directly correlate with progressive physiologic deterioration and shortened survival (1, 10).

Unfortunately, there is little other direct evidence to support recurrent epithelial injury, and no obvious source or mechanism for this injury has been identified. Given the absence of direct evidence for the prevailing theory, we considered alternative explanations for the fibroblast foci. We explored the hypothesis that, far from multiple discrete lesions, the young fibroblastic tissue that characterizes the fibroblast foci of the UIP lung is a complex interconnected neoplasm by reconstructing the UIP lung in three dimensions, performing stereologic analysis, and analyzing the clonality of these lesions.

## METHODS

### Clinical Material

Surgical lung biopsy specimens were obtained from subjects with IPF and cryptogenic organizing pneumonia (COP) who had been prospectively enrolled in our institutional review board–approved, Health Insurance Portability and Accountability Act of 1996 (HIPAA) compliant protocols. IPF was diagnosed on the basis of appropriate clinical features and UIP on surgical lung biopsy. UIP was diagnosed by the identification of a patchy, nonuniform, fibrosing interstitial pneumonia of variable distribution. Alternating zones of interstitial fibrosis, inflammation, honeycomb change, normal lung, and fibroblast foci were required. The interstitial fibrosis was characterized by eosinophilic collagen thickening alveolar septa and forming patchy scars with few associated inflammatory cells (Figures 1A and 1B) (11). COP was diagnosed by the identification of typical features including fibroblastic tissue in airspaces (Masson bodies; Figures 1C and 1D) on surgical lung biopsy in the appropriate clinical setting (11).

### Three-Dimensional Reconstruction

Serial sections 5-μm thick were cut over approximately 500 μm (approximately 100 sections) from surgical lung biopsies from four cases of UIP and one case of COP. Slides were stained with pentachrome (Movat), and digitally photomicrographed. These sections were manually

(*Received in original form February 10, 2006; accepted in final form May 30, 2006*)

Supported by NHLBI SCOR HL67671.

* These authors contributed equally to this manuscript.

Correspondence and requests for reprints should be addressed to Kevin K. Brown, M.D., National Jewish Center, 1400 Jackson Street, Denver, CO 80206. E-mail: brownk@njc.org

This article has an online supplement, which is accessible from this issue's table of contents at www.atsjournals.org

**Am J Respir Crit Care Med Vol 174. pp 654–658, 2006**
**Originally Published in Press as DOI: 10.1164/rccm.200602-205OC on June 23, 2006**
**Internet address: www.atsjournals.org**

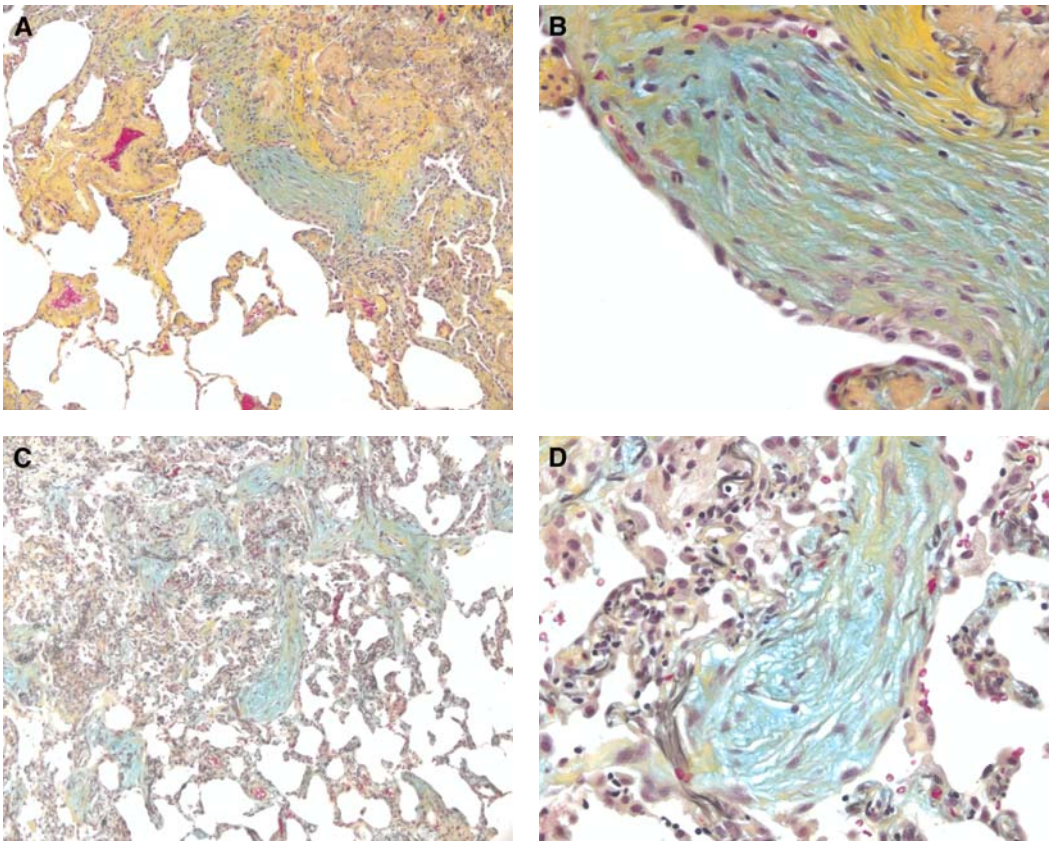


***Figure 1.*** Pentachrome-stained sections of usual interstitial pneumonia (UIP) are shown at 100× (*A*), with a high power (400×) view of a fibroblast foci (*B*). There is heterogeneous deposition of mature collagen (*yellow*) throughout the parenchyma with associated architectural distortion and focal deposits of young, immature collagen (*blue-green*) within the subepithelial interstitium. Pentachrome-stained sections of cryptogenic organizing pneumonia (COP) are shown at 100× (*C*), with a high power (400×) view of a Masson body (*D*). In contrast to the sections of UIP, there is minimal mature collagen deposition (*yellow*), and only young immature collagen (*blue-green*) is present within airways.

translated and rotated so that the consecutive images were coaligned with respect to clear features such as blood vessels and tissue boundaries, utilizing the pleura as the primary reference point (*see* Figure E1 in the online supplement). Analysis focused on the following features: pleura, macrophage clusters, pulmonary vessels, and interstitial fibroblast proliferation (fibroblast foci). The two-dimensional images were collated into three-dimensional structures using proprietary software written in C and C++ that imports the registered and colored images from a numbered series of image files and stores them in a three-dimensional data array. Missing levels (due to tissue ribbon breaks, etc.) were interpolated from adjacent sections using a percentage-closer interpolation technique. Two complementary methods were used to analyze the data array. For the first method, the freeware software Vis5D (University of Wisconsin, Madison, WI) was used to visualize the three-dimensional array. For the second method, the marching-cube algorithm (12) was used to create a polygon mesh along the isosurface of the volumetric data using a local density function of the given component of interest (e.g., fibroblastic tissue). The resulting polygon mesh was smoothed to remove spurious high-frequency detail that is artifactually created in the reconstruction due to finite sampling. The final polygon meshes were imported into Softimage XSI (Softimage Co., Montreal, PQ, Canada) for final rendering.

### Stereologic Analysis and Calculation of Euler Number

Stereologic analysis was performed using a light microscope on five subjects with UIP and one subject with COP. One block from each subject was analyzed for connectivity using multiple sections over 500 μm (range, 455–510 μm).

To calculate the Euler number, between 16 and 20 consecutive sections spaced every 20–30 μm were analyzed from each subject. Using the point-counting technique on serial sections, fibroblast foci, arteries, and macrophage clusters were identified. The connectivity of each of these features was then determined by the estimation of the Euler number (13, 14). For a two-dimensional network in a three-dimensional space, the Euler number (X) is a positive integer that indicates the extent (or redundancy) of connectivity in the network. The number of connections (here, the number of fibroblast foci) is proportional to the Euler number, and any value above zero indicates connectivity. A multiply connected structure such as a net has a higher Euler number than a simply connected structure such as a single-trunked tree. Using adjacent sections as physical dissectors for counting in both directions (i.e., using each single section once as a sampling section and once as a look-up section), we denoted fibroblast foci that spanned sections as bridges (B). Isolated fibroblast foci without connections to previously visible foci were denoted as islands (I). Areas entirely surrounded by tissue were denoted as holes (H). With dissectors used to count in both directions, the contribution from the dissector counts to the total Euler number (X) is then $X = H + B - I$ (where H = holes, B = bridges and I = islands). Additional details on calculating the stereologic estimators, including descriptions of all parameters and values from all six cases are shown in the online supplement (Tables E1 and E2).

### Analysis of Clonality

Surgical lung biopsy specimens from seven women with UIP and seven women with COP were analyzed. DNA from the endometrial adenocarcinoma cell line HEC-1-A (American Type Culture Collection, Rockville, MD) was used as a positive control for restriction digestion and polymerase chain reaction (PCR) amplification. To obtain samples for DNA analysis by PCR, we performed microdissection on the tissue sections to isolate the fibroblast foci and Masson bodies using an Arcturus Pix Cell II (Arcturus Bioscience, Mountain View, CA). The internal control consisted of tissue free of fibroblastic lesions. Clonality was determined with an adaptation of the human androgen receptor gene methylation assay. The methylation pattern of the DNA was examined using the methyl-sensitive restriction endonuclease HhaI (Invitrogen, Carlsbad, CA). Additional details are available in the online supplement.

## RESULTS

### Two-Dimensional Histopathology

The histologic appearance of UIP and COP are contrasted in Figure 1. UIP is a fibrosing interstitial pneumonia that exhibits

architectural distortion, little cellular inflammation, spatial and temporal heterogeneity with advanced interstitial fibrosis, and essentially normal parenchyma within the same microscopic field. In addition to the deposition of mature collagen (yellow in the pentachrome stain), immature collagen (stained blue-green) appears as interstitial foci projecting into the airspaces. On two-dimensional section, these individual foci appear independent and discrete. In contrast, COP is an airspace-filling process that leaves the interstitium largely uninvolved with little architectural distortion. The individual plugs of fibroblastic tissue (Masson bodies) appear to fill the entire airspace, from the small airway to the alveolus.

### Analysis of Connectivity

To evaluate the connectivity of the fibroblast foci in UIP and Masson bodies in COP, we imaged multiple serial sections of tissue and built a three-dimensional representation of the fibroblastic tissue, blood vessels, and macrophage clusters. Stereoscopic analysis was then used to provide a quantitative description of the connectivity. The resulting Euler numbers for the fibroblastic tissue are presented in Table 1. As expected, blood vessels showed connectivity with a Euler number of 2, whereas macrophage clusters exhibited no connectivity (a Euler number of 0). The fibroblast foci show significant connectivity with Euler numbers ranging from 19 to 39 (*see* online supplement for complete data). Table E1 provides final Euler numbers for each case and shows depth of tissue studied. Table E2 shows detailed datasets for the UIP and COP cases.

### Three-Dimensional Reconstruction

In addition to the connectivity suggested by the Euler number, computer generated three-dimensional models provide a visual and intuitive presentation of the data (Figures 2 and 3). When viewed in three dimensions, the isolated fibroblast foci appear as an interconnected network, forming a "fibroblast reticulum" expanding into the underlying tissue and closely intertwined with an extensive and abnormal vascular network.

### Analysis of Clonality

The identified interconnectivity of the fibroblast reticulum in UIP raised the possibility of a monoclonal, malignant process as the mechanism for the progression of UIP. Surgical lung biopsy specimens from seven women with COP and seven women with UIP were microdissected and analyzed using the human androgen receptor gene methylation assay. HEC-1-A endometrial adenocarcinoma cells were used as a positive control. Figure 4 shows the *HhaI* digested PCR products from representative cases of UIP and COP. All of the patients showed balanced methylation patterns, consistent with polyclonality. Only the positive control, HEC-1-A, showed unbalanced methylation consistent with monoclonality. The data from analysis of all the specimens are in the online supplement (Table E3). The corresponding normal tissues had inactivation ratios between 0.87 and 1.41, and were used to correct for alterations in clonality ratio due to lyonization. Thus, both UIP and COP are polyclonal proliferations of fibroblasts.

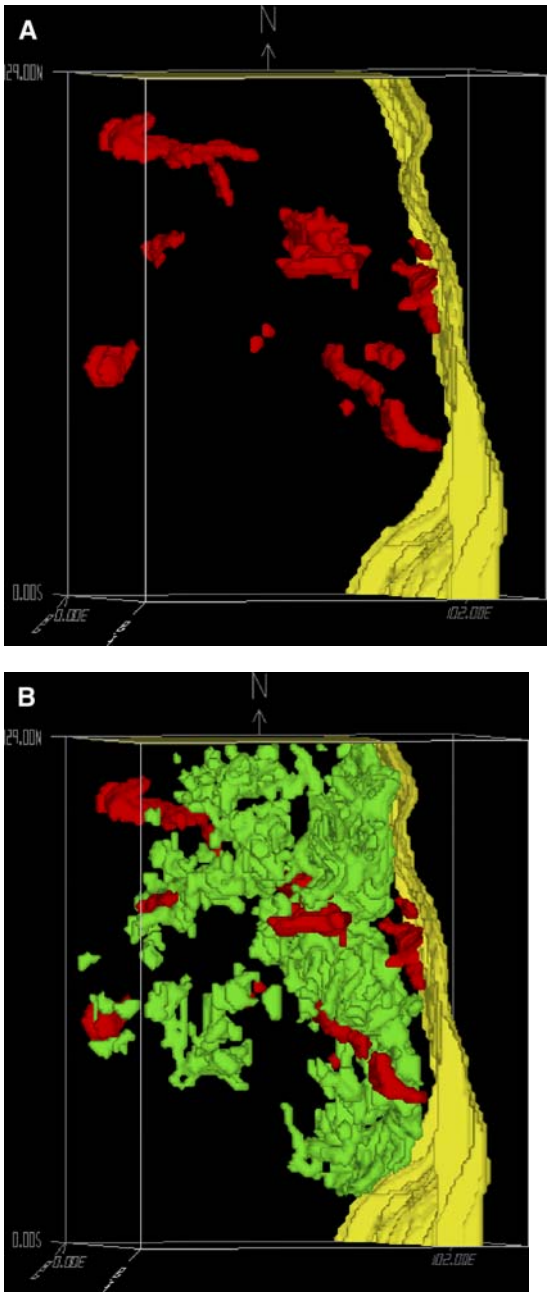


*Figure 2.* Computer-generated three-dimensional reconstructions of (*A*) pleural surface (*yellow*) and blood vessels (*red*) and (*B*) with the fibroblast reticulum added (*green*).

**TABLE 1. STEREOSCOPIC ANALYSIS OF CRYPTOGENIC ORGANIZING PNEUMONIA AND USUAL INTERSTITIAL PNEUMONIA DEFINING THE EXTENT OF INTERCONNECTEDNESS BY EULER NUMBERS**

| | COP | UIP | | | | |
|---|---|---|---|---|---|---|
| | Case 1 | Case 2 | Case 3 | Case 4 | Case 5 | Case 6 |
| Euler number | 26 | 38 | 32 | 26 | 39 | 19 |

The extent of connectivity is directly proportional to the Euler number.

## DISCUSSION

Despite considerable recent investigation of IPF/UIP, neither the initial cause nor the reasons for progression are known. With few clinical clues, the histopathologic pattern of UIP with its combination of normal lung, mature fibrosis, honeycomb change, and fibroblast foci has been a primary source of hypothesis generation regarding pathobiology. A number of studies, dating from the original description of the fibroblast foci in the 1980s (5), have focused attention on their clinical relevance (1, 15, 16).




***Figure 3.*** Computer-generated three-dimensional reconstructions of UIP (*A*) and COP (*B*). In this rendering, fibroblastic tissue is *white*, blood vessels are *red*, and the pleural surface is *brown*.

On individual tissue sections these foci are identified as isolated lesions, suggesting that discrete, localized episodes of acute lung injury with an abnormal repair response may account for the initial lesion, and that recurrent episodes may account for the progression of IPF (2). Unfortunately, there is little direct evidence to support recurrent epithelial injury, and no obvious source or mechanism for the injury. Given the limited evidence for recurrent discrete episodes of lung injury, we hypothesized that, rather than isolated lesions, the fibroblast foci of the UIP lung are an interconnected neoplasm. By reconstructing the UIP lung in three dimensions, performing stereologic analysis, and analyzing the clonality of these lesions, we sought to determine whether these foci are part of an organized reticulum, and whether this reticulum is malignant.

The prevailing hypothesis predicts that reconstruction should identify discrete, isolated fibroblast foci. If this were true, stereologic analysis should identify discrete entities with a Euler number of 0, similar to isolated macrophage clusters; and three-dimensional reconstruction would confirm them as islands of tissue. In contrast, we demonstrate that these foci are part of a continuous fibrotic reticulum that extends from the pleural surface into the lung parenchyma. This structure raises the possibility of a malignant neoplasm growing through the lung or a reactive process responsive to local environmental stimuli. To explore this question, we performed clonality analysis on the fibroblastic tissue.

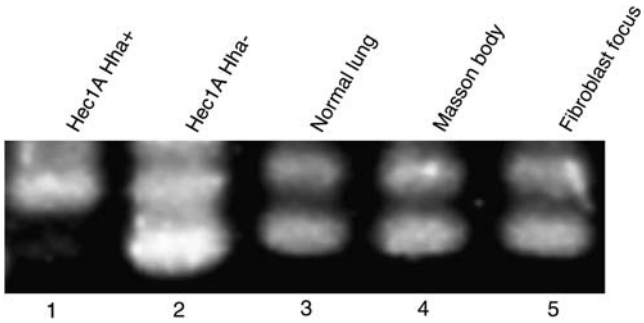


***Figure 4.*** Clonality analysis based on human androgen receptor gene methylation assay polymerase chain reaction of DNA from HEC1A; endometrial adenocarcinoma cells are presented with and without digestion by *HhaI*. A fibroblast focus of UIP, uninvolved (normal) lung, and a Masson body of COP, are presented after digestion by *HhaI*. In UIP and COP, two parental alleles are present after *HhaI* digestion representing the balanced methylation pattern and a polyclonal population of cells. In the uninvolved (normal) lung, both alleles are amplified equally after *HhaI* digestion, excluding the possibility of unequal lyonization of normal tissue.

Despite the high level of connectivity seen among the fibroblast foci of UIP, clonality analysis reveals that it is a polyclonal proliferation, rather than a monoclonal population of fibroblasts. This suggests that UIP/IPF is not malignant but reactive. The mechanism responsible for this reaction remains elusive; however, a number of possibilities exist. This phenotypic transformation of lung fibroblasts may be due to a persistent localized autoimmune stimulus (17, 18), a chronic infectious process with both latent and active phases such as a $\gamma$ herpes virus (19), or selection of specific subsets of lung fibroblasts or circulating mesenchymal stem cells followed by localization and polyclonal expansion.

In conclusion, we have found that the fibroblast foci of UIP, far from being isolated discrete sites of focal lung injury, form a highly complex and interconnected, nonmalignant reticulum extending from the pleura into the lung parenchyma. These findings argue against the underlying biological cause of UIP being the result of multiple, small, focal, and isolated episodes of epithelial injury followed by a pathologic fibrotic repair mechanism. This concept, of a "wave" of fibrosis progressing through the lung, alters our underlying assumptions regarding the initiation and progression of IPF and suggests new hypotheses for the initiation and progression of fibrosing lung disease.

***Conflict of Interest Statement***: None of the authors has a financial relationship with a commercial entity that has an interest in the subject of the manuscript.

***Acknowledgment***: The authors thank Drs. Dallas Hyde and Jens Randel Nyengaard for assistance with stereology, Ms. Lisa Litzenberger for expert assistance with digital imaging, and Ms. Jane Parr for expert assistance with histology support.

## References

1. King TE Jr, Tooze JA, Schwarz MI, Brown KR, Cherniack RM. Predicting survival in idiopathic pulmonary fibrosis: scoring system and survival model. *Am J Respir Crit Care Med* 2001;164:1171–1181.

2. Selman M, King TE, Pardo A. Idiopathic pulmonary fibrosis: prevailing and evolving hypotheses about its pathogenesis and implications for therapy. *Ann Intern Med* 2001;134:136–151.
3. King TE Jr, Safrin S, Starko KM, Brown KK, Noble PW, Raghu G, Schwartz DA. Analyses of efficacy end points in a controlled trial of interferon-gamma1b for idiopathic pulmonary fibrosis. *Chest* 2005;127: 171–177.
4. Daniil ZD, Gilchrist FC, Nicholson AG, Hansell DM, Harris J, Colby TV, du Bois RM. A histologic pattern of nonspecific interstitial pneumonia is associated with a better prognosis than usual interstitial pneumonia in patients with cryptogenic fibrosing alveolitis. *Am J Respir Crit Care Med* 1999;160:899–905.
5. Myers JL, Katzenstein AL. Epithelial necrosis and alveolar collapse in the pathogenesis of usual interstitial pneumonia. *Chest* 1988;94:1309–1311.
6. Katzenstein AL, Myers JL, Prophet WD, Corley LS 3rd, Shin MS. Bronchiolitis obliterans and usual interstitial pneumonia: a comparative clinicopathologic study. *Am J Surg Pathol* 1986;10:373–381.
7. Fukuda Y, Basset F, Ferrans VJ, Yamanaka M. Significance of early intra-alveolar fibrotic lesions and integrin expression in lung biopsy specimens from patients with idiopathic pulmonary fibrosis. *Hum Pathol* 1995;26:53–61.
8. Kuhn C, McDonald JA. The roles of the myofibroblast in idiopathic pulmonary fibrosis: ultrastructural and immunohistochemical features of sites of active extracellular matrix synthesis. *Am J Pathol* 1991; 138:1257–1265.
9. Kuhn C 3rd, Boldt J, King TE Jr, Crouch E, Vartio T, McDonald JA. An immunohistochemical study of architectural remodeling and connective tissue synthesis in pulmonary fibrosis. Am Rev Respir Dis 1989; 140:1693–1703.
10. Nicholson AG, Fulford LG, Colby TV, du Bois RM, Hansell DM, Wells AU. The relationship between individual histologic features and disease progression in idiopathic pulmonary fibrosis. *Am J Respir Crit Care Med* 2002;166:173–177.
11. American Thoracic Society/European Respiratory Society. International multidisciplinary consensus classification of the idiopathic interstitial pneumonias. *Am J Respir Crit Care Med* 2001;165:277–304.
12. Lorensen WE, Cline HE. Marching cubes: a high resolution 3D surface reconstruction algorithm. *Comput Graph (ACM)* 1987;21:163–169.
13. Ochs M, Nyengaard JR, Jung A, Knudsen L, Voigt M, Wahlers T, Richter J, Gundersen HJ. The number of alveoli in the human lung. *Am J Respir Crit Care Med* 2004;169:120–124.
14. Gundersen HJ, Bagger P, Bendtsen TF, Evans SM, Korbo L, Marcussen L, Moller A, Nielsen K, Nyengaard JR, Pakkenberg B, *et al.* The new stereological tools: disector, fractionator, nucleator and point sampled intercepts and their use in pathological research and diagnosis. *APMIS* 1988;96:857–881.
15. Flaherty KR, Colby TV, Travis WD, Toews GB, Mumford J, Murray S, Thannickal VJ, Kazerooni EA, Gross BH, Lynch JP 3rd, *et al.* Fibroblastic foci in usual interstitial pneumonia: idiopathic verses collagen vascular disease. *Am J Respir Crit Care Med* 2003;167:1410–1415.
16. Nicholson AG, Fulford LG, Colby TV, du Bois RM, Hansell DM, Wells AU. The relationship between individual histologic features and disease progression in idiopathic pulmonary fibrosis. *Am J Respir Crit Care Med* 2002;166:173–177.
17. Buyon JP, Clancy RM. Autoantibody-associated congenital heart block: TGFbeta and the road to scar. *Autoimmun Rev* 2005;4:1–7.
18. Wallace WA, Schofield JA, Lamb D, Howie SE. Localisation of a pulmonary autoantigen in cryptogentic fibrosing alveolitis. *Thorax* 1994;1994: 1139–45.
19. Mora AL, Woods CR, Garcia A, Xu J, Rojas M, Speck SH, Roman J, Brigham KL, Stecenko AA. Lung infection with gamma-herpesvirus induces progressive pulmonary fibrosis in th2-biased mice. *Am J Physiol Lung Cell Mol Physiol* 2005;289:L711–L721.